

CASE REPORT

Actinomyces Israelii Infection

Xiao-Li Huang¹, Wei Zhang^{*,2,3}, Guo-Ming Zhang^{*,2,3}

** The three authors are co-first authors and contributed equally to this work*

¹ Department of Laboratory Medicine, Sihong People's Hospital, Sihong, China

² Department of Laboratory Medicine, Shuyang Hospital Affiliated to Xuzhou Medical University, Shuyang, China

³ Department of Laboratory Medicine, Shuyang People's Hospital, Shuyang, China

(Clin. Lab. 2019;65:xx-xx. DOI: 10.7754/Clin.Lab.2018.181020)

Correspondence:

Guo-Ming Zhang
Department of Laboratory Medicine
Shuyang Hospital Affiliated to
Xuzhou Medical University
Shuyang People's Hospital
No. 9 Yingbin Road
Shuyang, Jiangsu 223600
P.R. China
ORCID: 0000-0003-0662-1302
Email: zly52120@163.com
gm@xzhmu.edu.cn

Case Report accepted October 19, 2018

Supplementary Figures.

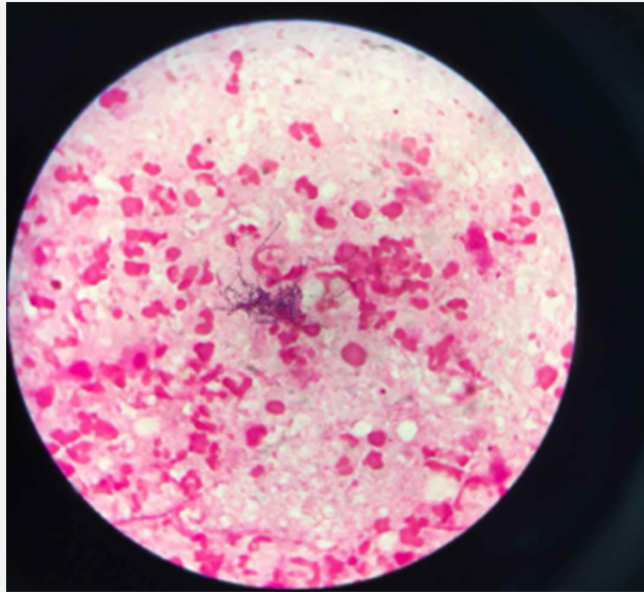


Figure 1. Gram stain of fluid specimen.

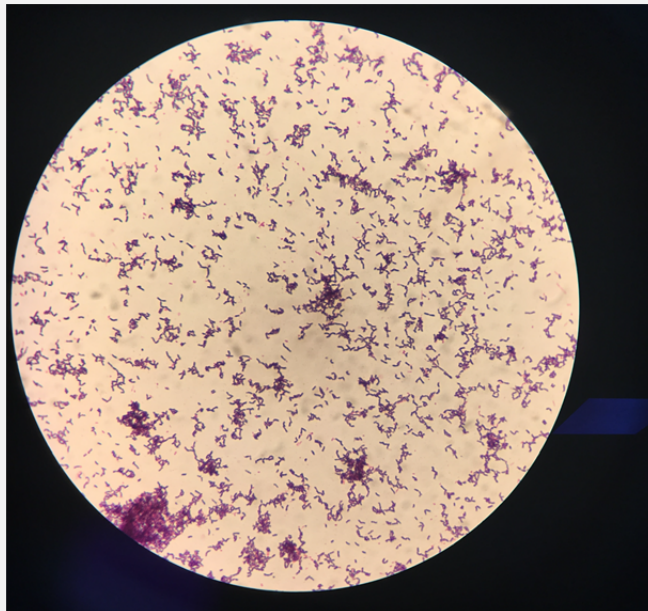


Figure 2. Gram stain after culture.

Actinomyces Israelii Infection

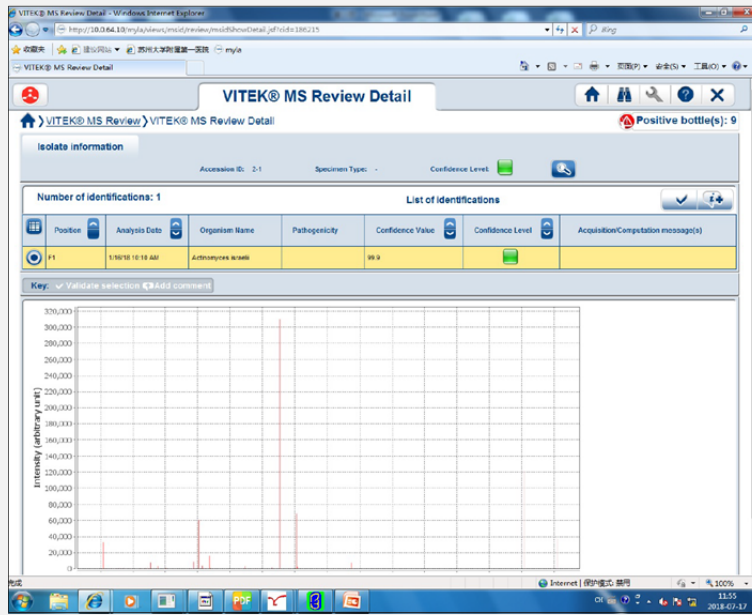


Figure 3. Mass spectrometry showing *Actinomyces israelii*.